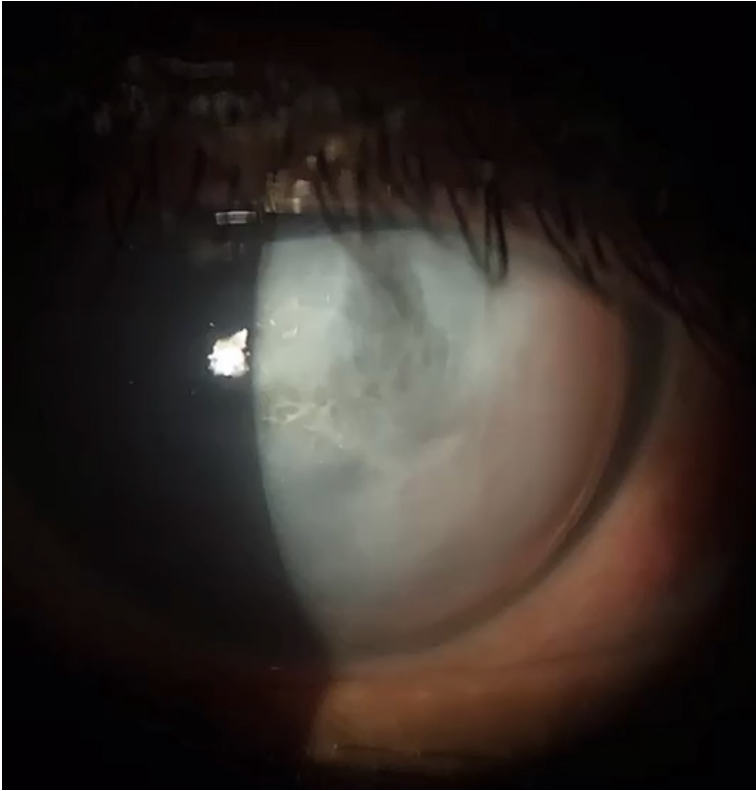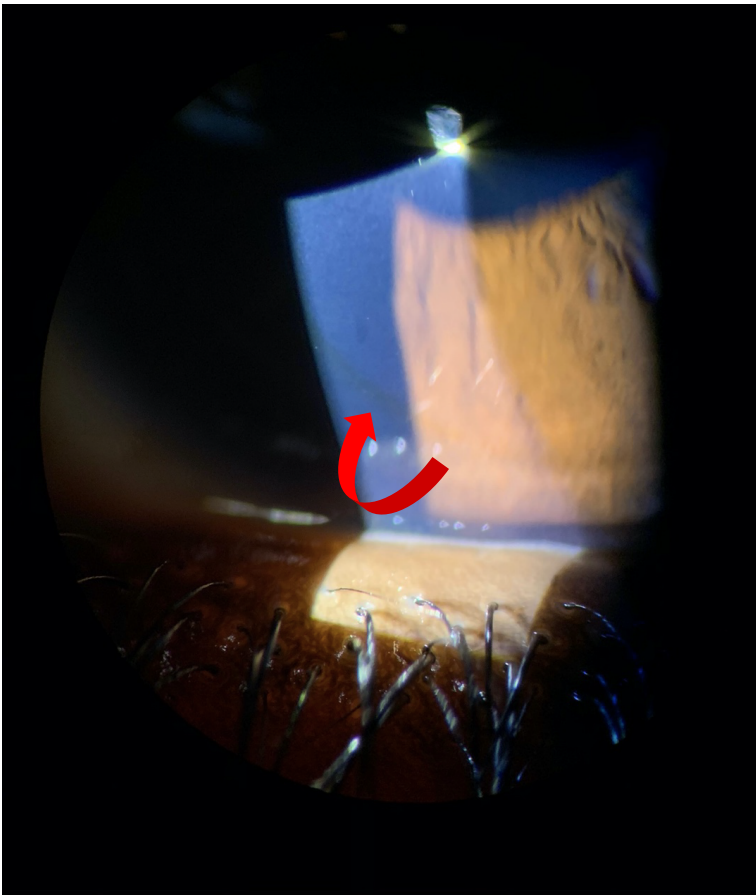


The Cornea Corner: Example of slit lamp documentation of keratoconus findings



Large corneal protrusion and significant opacity due to hydrop with overlying bullae and 4+ edema within central 4mm, epithelium intact.

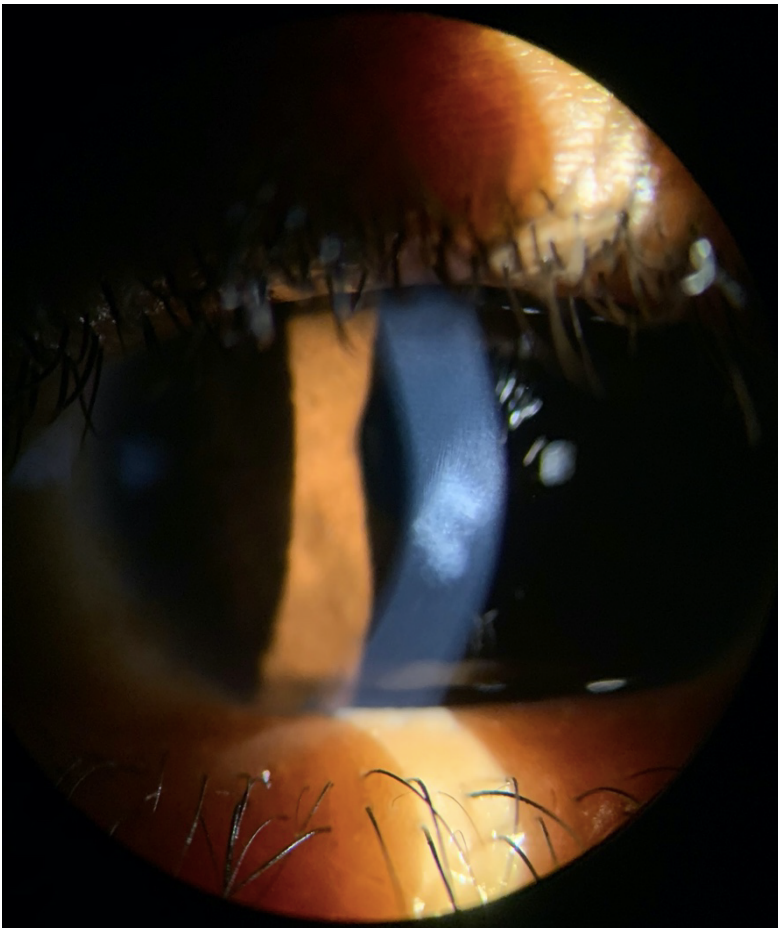
Anterior chamber: Unable to assess due to opaque cornea



Inferior peripheral
Fleischer's Ring (remember
to utilize a cobalt blue filter
for improved visualization)



Small 0.3mm dense paracentral scar located just inferior to pupillary border with surrounding Vogt's striae



Apical steepening and thinning with dense inferior paracentral scar and Vogt's striae